



Daljit S Gill

John Hobkirk, Steven Bassi, Ken Hemmings and Jane Goodman

# Counselling Patients with Hypodontia

**Abstract:** The aim of this article is to outline the implications that a diagnosis of severe hypodontia can have on a family. This should help dentists to provide effective counselling for such patients. We will discuss the dental, psycho-social, medical, functional, educational and financial implications that this diagnosis can bring.

**Clinical Relevance:** Hypodontia is a common clinical condition encountered by general dental practitioners. Effective counselling of patients affected by this condition will help a family prepare for the implications of this diagnosis and help to improve patient satisfaction.

**Dent Update 2008; 35: XXX-XXX**

Hypodontia is the developmental absence of teeth excluding the third molars. The prevalence of hypodontia is reported to be between 4.6–6.3% within the permanent dentition of white European populations.<sup>1</sup> Females are affected more frequently than males and the most commonly missing

teeth are the mandibular second premolars, the maxillary lateral incisors and the maxillary second premolars.<sup>1</sup> It is estimated that 2.6% of patients with hypodontia suffer from severe hypodontia, which is the absence of six or more teeth (overall population prevalence 0.14–0.3%).<sup>1,2</sup>

The diagnosis of hypodontia can have a number of implications for the affected individual and their family. This is particularly the case for a diagnosis of severe hypodontia or anodontia (the total absence of teeth). This diagnosis can carry a number of dental, psycho-social, medical, functional, educational and financial implications.<sup>3</sup> Ideally, patients and immediate family members should be counselled about such implications when a diagnosis of severe hypodontia is made, to enable the family to prepare for these issues and minimize their future impact.

The aim of this article is to outline the implications of a diagnosis of severe hypodontia for a family, which should help dentists to provide effective counselling for such patients. The following

- factors will be considered:
- Dental implications
- Psycho-social implications
- Medical implications
- Functional implications

- Educational implications
- Financial implications

## Dental implications

### Importance of dental disease prevention

In patients with a reduced number of teeth, the importance of maintaining the teeth which are present in a healthy condition should be emphasized. Preventive techniques which should be considered include:

- Diet analysis and advice;
- Oral hygiene instruction including techniques for keeping microdont spaced teeth clean;
- Fissure sealing;
- Fluoride supplementation;
- Sports guards to protect protrusive maxillary incisors;
- Artificial saliva in patients with xerostomia (eg Ectodermal Dysplasia).

### Treatment involved

The management of hypodontia should involve a multidisciplinary team approach including the following areas of expertise in addition to the general dental practitioner:

- Paediatric Dentistry;

**Daljit S Gill**, BSc, BDS, FDS RCS, MSC, MOrth, FDSOrth RCS, Consultant/Honorary Senior Lecturer, UCL Eastman Dental Hospital, UCLH NHS Foundation Trust and Great Ormond Street Hospital for Children NHS Trust, London, **Steven Jones**, ??????????, Consultant Orthodontist/Honorary Senior Lecturer/Director of Orthodontic Education, UCL Eastman Dental Hospital and UCLH NHS Foundation Trust, **John Hobkirk**, ??????????, Professor of Prosthetic Dentistry/Head of Prosthetics **Steven Bassi**, ?????????, Consultant in Restorative Dentistry, **Ken Hemmings**, ?????????, Consultant in Restorative Dentistry/Honorary Lecturer, **Jane Goodman**, ?????????, Consultant in Paediatric Dentistry/Honorary Senior Lecturer, UCL Eastman Dental Hospital and UCLH NHS Foundation Trust, UK.



Age	Treatment	Comments
<6 years (preschool) (Deciduous Dentition)	Removable dentures for psychological and functional reasons.	Will require regular adjustments during growth. Retention and stability may be problematic in those with poorly developed alveolar ridges.
7-12 years (Mixed Dentition)	Composite build-ups to improve aesthetics of microdont permanent teeth or worn deciduous teeth.  Removable dentures.  Consider interceptive extractions to guide eruption.  Simple orthodontic treatment for space redistribution.	Problems may include palatal maxillary canines and infraocclusion.  eg a diastema that cannot be closed restoratively. Long-term retention will be required.
>12 years (Permanent dentition)	Orthodontic treatment  Resin-bonded bridges following orthodontics for tooth replacement.  Composite build ups of microdont or hypoplastic teeth.  Overdentures (severe hypodontia)	Pontics can be placed on the fixed appliance and the retainer following orthodontics as a temporary measure.  Other methods of tooth replacement include maintaining the deciduous predecessor, dentures, fixed bridges and transplantation.  Disguising intense hypoplastic patches can be difficult.  Abutments help maintain alveolar bone, improve retention and stability and provide proprioception.
16-20 years	Single tooth implants or implant fixed bridges or implant-retained overdentures.  Orthodontics in combination with orthognathic surgery.	Placed when the majority of growth is complete. Tends to be earlier in females (17 years) than males (18 years). Bone augmentation procedures may be required before implant placement.  For patients with severe skeletal discrepancies.

**Table 1.** Treatment approaches for the management of hypodontia.

- Orthodontics;
- Restorative Dentistry;
- Oral Surgery;
- Genetic Science;
- Clinical Behavioural Psychology.

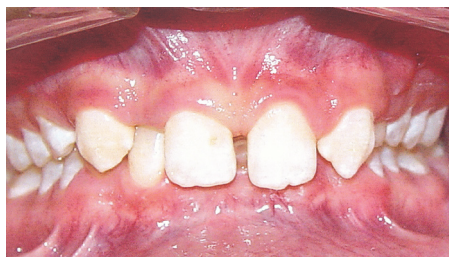Patients may be referred between these different professionals and it is important that they understand the

role of each individual and the importance of effective communication within the team.

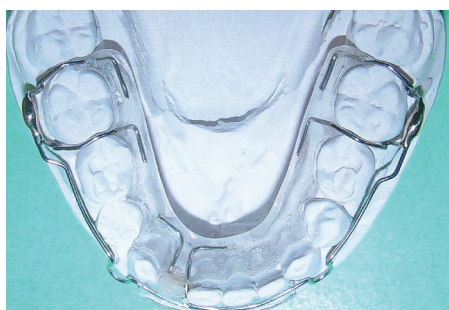#### ***Deciduous dentition***

Typical treatment approaches for the management of hypodontia are

outlined in Table 1. In patients with severe hypodontia or anodontia, early treatment may involve the placement of removable dentures to help improve aesthetics and function.<sup>2</sup> These can be placed at a very young age but are especially important psychologically just before the start of schooling years. Surprisingly, children



**Figure 1.** Spacing may become apparent following the eruption of the permanent dentition and often triggers a request for treatment as in this patient with missing maxillary lateral incisors.

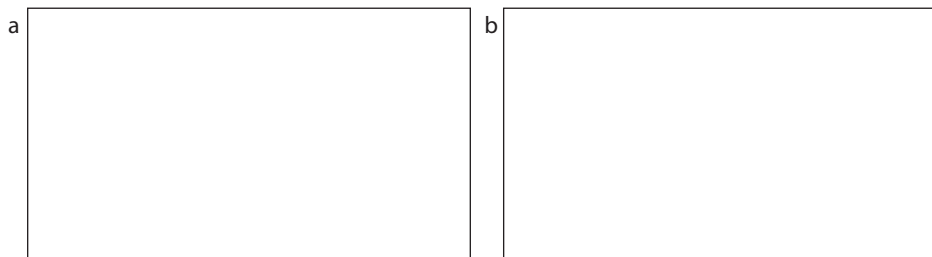


**Figure 3.** Retainers are used following orthodontic treatment. This is a modified Hawley retainer, which has an acrylic labial bow soldered to the first molar Adams clasps and a pontic replacing the missing lower right lateral incisor. The pontic restores appearance and helps maintain space.

often cope with dentures and adaptation can be helped by providing a prosthesis made for the arch with the best denture prognosis first. Parents should be warned about the problems related to dentures, including initial speaking difficulties, dietary limitations, loss of the appliance and the need for adjustments, relining and replacement. The early use of such appliances can be of great benefit in social development and has been reported as helping speech development.<sup>4</sup>

### Mixed dentition

In children with less severe hypodontia the psychological impact may not be apparent until eruption of the permanent incisors when the child may notice spacing and be teased at school (Figure 1). If the psychological impact is significant, it may be appropriate to build up microdont teeth with composite resin to help close space (Figure 2)<sup>5</sup> or provide dentures to replace anterior missing teeth. Simple orthodontic treatment



**Figure 2.** Microdont spaced teeth (a) can be disguised effectively using composite resin build-ups (b).

can also be considered at this stage (eg diastema closure), but this does then commit the patient to wearing fixed or removable retainers for a number of years until definitive orthodontic treatment is commenced. This form of treatment can be very taxing on parents as appliances need regular review and may reduce later patient compliance. There may also be an impact on oral health when such appliances are used for long periods and not maintained appropriately or when oral hygiene is inadequate.

### Permanent dentition

Once in the permanent dentition, patients will require a joint orthodontic-restorative assessment. Generally speaking, cases with severe hypodontia require more restorative than orthodontic input, whilst milder cases can sometimes be treated with the use of orthodontics alone. Because of the general delay in dental development in patients with hypodontia, orthodontic treatment may commence at a later age compared to family and school friends not affected by the condition. Patients and parents can be warned that this may be the case at an early stage to reduce later frustration.

Fixed orthodontic treatment is often undertaken to correct any superimposed malocclusion, to close or open missing tooth spaces and to make roots parallel. Treatment typically takes 18–24 months, but can take longer, and patients need to attend for adjustments at 6–8 week intervals. They may also need to attend in between appointments if there are any breakages and this can often be time consuming for parents and patients. Patients with hypodontia may be more prone to fixed appliance breakages for a number of reasons:

- Orthodontic bracket bases do not conform as well to teeth with atypical crown morphology;
- Long spans of unsupported archwire may subject brackets to high shear forces from the occlusion;

If orthodontic treatment is carried out to open anterior spaces, patients can often become conscious of the gap that is created. It is possible to place an acrylic tooth with a bonded bracket into such a space for aesthetic enhancement during fixed appliance treatment. Once orthodontic treatment is complete, patients will need to wear retainers and it is possible to place a prosthetic tooth on the retaining appliance for aesthetic reasons and as an aid to space maintenance (Figure 3). Before orthodontic appliances are removed, it is essential that the clinician who will undertake the definitive restorative treatment examines the patient to ensure that the correct space has been created. It is also worthwhile taking periapical radiographs to ensure that the roots do not intrude on edentulous spaces as such encroachment may complicate or prevent future implant treatment.

Patients are often ready to consider wearing their retainers on a part-time basis following the first year of retention. This is often a good time to have resin-bonded bridges placed so that the retainers can be worn part-time. It is important for the restorative dentist to liaise with the orthodontist closely so that the retainer can be adjusted with the bridgework in place, to avoid a period where the patient is left without an appliance. Restorative treatment may be carried out by the patient's general dental practitioner or by the community and hospital dental services.

Orthodontic retention may be

	Advantages	Disadvantages
Before Orthodontics	Restoration acts as a space maintainer during treatment.	Space may not be available before treatment for a build-up.  Altering the crown morphology may result in incorrect bracket placement.  The restoration is at risk of damage during bracket removal at completion of the orthodontic treatment.
During Orthodontics	Excess space can be created temporarily to aid mesial and distal restorative finishing.  Restoration acts as a space maintainer.	Gingival inflammation can jeopardize bonding and ideal finishing.  If composite is added to the labial surface of the tooth it may be necessary to drop down archwires to correct the in-out tooth position.
After Orthodontics	Allows gingival inflammation to subside after appliance removal.	A new retainer may need to be constructed after completion of restorative treatment. More difficult to finish interproximally correctly.

**Table 2.** Timing of restorative treatment of microdont teeth.

a consideration in the design of a resin-bonded bridge. It may be possible to incorporate a groove within the framework to allow the subsequent placement of a twistflex wire retainer. Alternatively, a fixed-fixed adhesive bridge design may be utilized to prevent orthodontic relapse, although careful follow-up will be required to ensure one of the bridge retainers does not debond. If this is not noticed, there is a risk of caries developing in the affected abutment and drifting of the debonded tooth.

Composite build-ups of microdont teeth can be undertaken before, during or after orthodontic treatment. Table 2 summarizes the advantages and disadvantages of each approach. Advances in composite technology have allowed this treatment to be used in a wide range of clinical situations. Its minimally invasive nature is particularly attractive in patients affected by hypodontia, who often present at a relatively young age. Composite resin is particularly useful to use during growth as it is easily modified as the gingival margins

mature. Porcelain veneers or bonded crowns offer superior aesthetics but should only be considered once the gingival margins are fully mature at the completion of facial growth. Patients/parents should be made aware of the requirement for the lifelong maintenance and replacement of all restorative procedures.

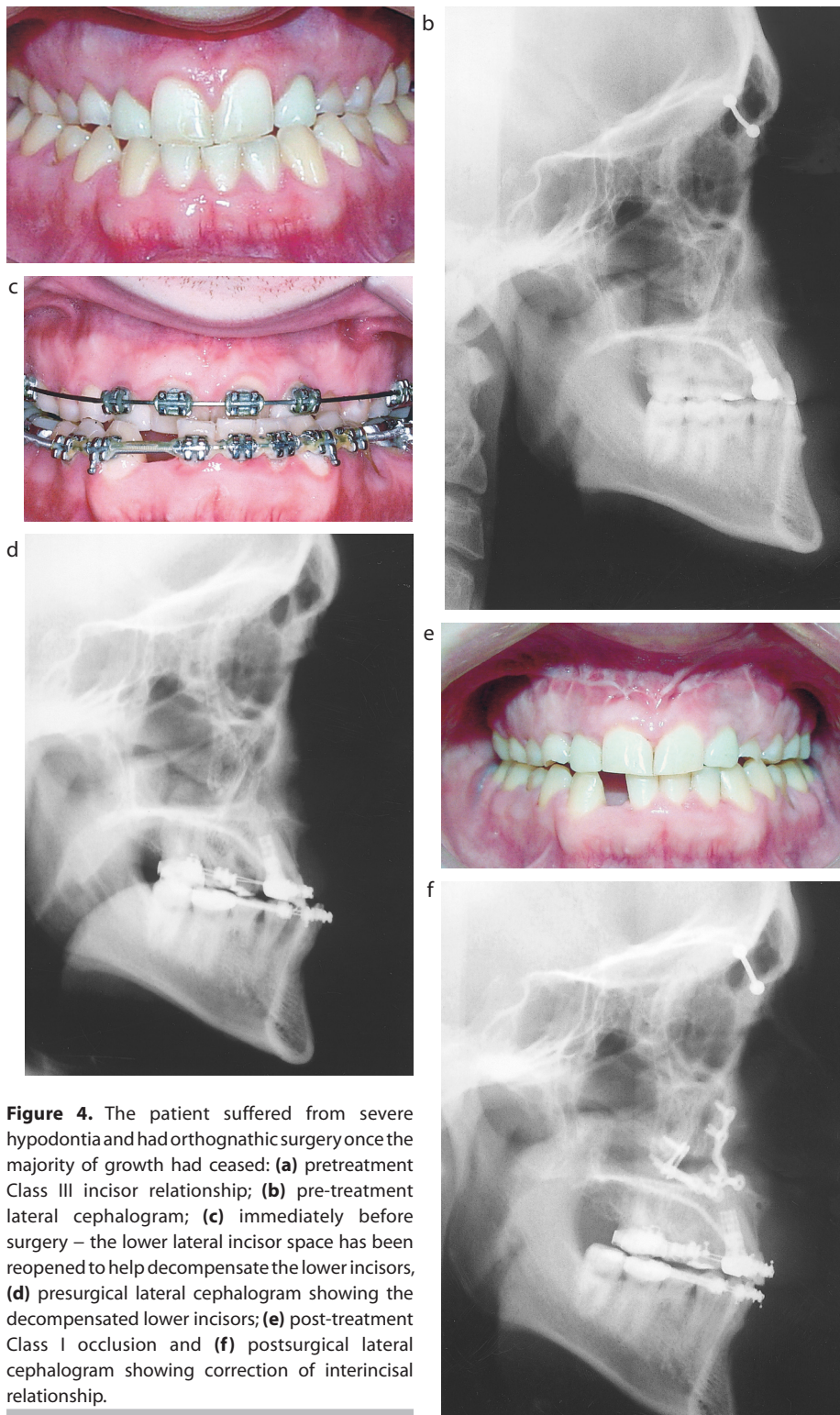
In patients with severe hypodontia, removable dentures may be the most effective treatment option until implant-retained prostheses can be offered. Overdentures can provide a useful treatment option in those patients with a few available teeth as they can help improve the stability and retention of appliances, permit changes to the occlusal vertical dimension in patients with an increased freeway space and provide lip support (Figure 4). Retained roots may also encourage the maintenance of alveolar bone volume. However, if roots are retained, it is essential that patients have good dietary and plaque control and also remove the dentures at sleeping times or there is a high risk of caries developing in the

abutments.

Definitive implant therapy should only be considered once the majority of vertical skeletal growth has occurred. Earlier implant placement has the risk of implants being incorrectly positioned in relation to the mature dentition owing to continued dento-alveolar development. Generally, vertical growth of the face has reduced to an acceptable level by the age of 17 years in females and 18 years in males. However, these are only mean values and there can be considerable individual variation, so it may be helpful to consider the results of serial standing height measurements and cephalograms when considering individual patients. When discussing implant treatment, it is important to make patients/parents aware of the possible need for bone grafting procedures.

Although some clinicians have placed implants in children affected by severe hypodontia as young as 3 years,<sup>6</sup> particularly in the lower incisor region, this treatment cannot be generally





**Figure 4.** The patient suffered from severe hypodontia and had orthognathic surgery once the majority of growth had ceased: **(a)** pretreatment Class III incisor relationship; **(b)** pre-treatment lateral cephalogram; **(c)** immediately before surgery – the lower lateral incisor space has been reopened to help decompensate the lower incisors, **(d)** presurgical lateral cephalogram showing the decompensated lower incisors; **(e)** post-treatment Class I occlusion and **(f)** postsurgical lateral cephalogram showing correction of interincisal relationship.

recommended in the absence of properly controlled trials.

Finally, orthodontics in

combination with orthognathic surgery may be considered in those patients with skeletal discrepancies that cannot be

dentally compensated for by the use of orthodontics alone. Patients with severe hypodontia often have a tendency to a skeletal III pattern with a reduced lower anterior face height.<sup>7</sup> Surgical treatment should only be undertaken when facial growth is complete and the true extent of the skeletal discrepancy can be evaluated.

### Screening siblings

It is important to take a family history when a child is diagnosed with hypodontia because of the genetic association of this condition.<sup>3</sup> Often, the affected patient will have a younger sibling and it is beneficial to suggest to the parent that the brother or sister be screened for hypodontia at an early stage. This will allow the patient to receive preventive advice and possible interceptive treatment at an appropriate time, which may simplify later treatment.

## Psycho-social implications

### Bullying

Bullying within school children is a very common problem, with up to 21% of children having reported being bullied at some stage.<sup>9</sup> Chronic bullying can lead to depression, loneliness, anxiety, low self-esteem and underachievement at school.<sup>9-11</sup> Children who bully tend to focus on one characteristic of the victim that is considered a weakness. However, if this focus is removed, they are likely to find a second focus, as it is often more general factors about the individual which initiate the bullying, such as general attractiveness, odd mannerisms or physical disabilities.

Hypodontia can impact significantly on dental aesthetics. Factors which contribute to a decrease in dental aesthetics include:

- The severity of hypodontia;
- Abnormalities in tooth shape especially microdontia;
- Abnormal tooth positions (eg a canine replacing a lateral incisor);
- The number of healthy retained deciduous teeth;
- Steps in the occlusal plane between permanent and deciduous teeth.

Features such as spacing may become a focus for bullies and parents may insist upon treatment on this basis. It

### Clinical Manifestations of Ectodermal Dysplasias

#### Skin

- Dry and scaling
- Hypopigmentation
- Dermatitis

#### Sweat glands

- Reduced or absent sweating
- Reduced heat tolerance

#### Hair follicles

- Sparse fair hair
- Alopecia
- Eyebrows or eyelashes absent/sparse

#### Nails

- Leukonychia
- Dystrophic and malformed

#### Dental

- Hypodontia or Anodontia
- Malformed teeth (cone- or peg-shaped)
- Prone to caries owing to enamel defects and xerostomia

#### Salivary glands

- Aplasia
- Xerostomia

#### Face

- Cleft lip/palate
- Frontal bossing
- Depressed nasal bridge
- Class III skeletal pattern
- Reduced face height

#### Eyes

- Corneal dysplasias
- Cataract
- Defective lacrimation

#### Nose

- Rhinitis
- Epistaxis

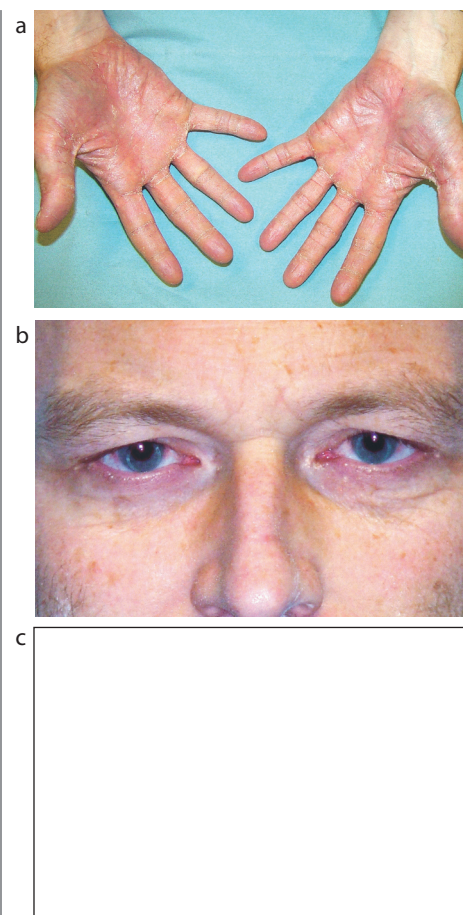
**Table 3.** The clinical features of Ectodermal Dysplasia.

is important to make parents aware that correcting the spacing may not stop bullying as one focus can be replaced by another. Advice and support for parents and victims on the management of this problem can be found on the following website **www.bullying.co.uk**

Simple treatment measures that can be used to reduce the impact of spacing

on dental aesthetics temporarily include:

- Tooth replacement using removable dentures;
- Modification of tooth form with composite resin to increase the size and improve the colour of deciduous and permanent teeth;
- Orthodontic treatment to close small areas of spacing.



**Figure 5.** Three features of Ectodermal Dysplasia: (a) dry eczematous skin due to absence of sweat glands, (b) absence of the majority of the lower eyelashes and (c) anodontia.

### Medical implications

Hypodontia can be a feature of a number of medical conditions including the Ectodermal Dysplasias, Down's syndrome, Hemifacial Microsomia and Van der Woude syndrome. Hypodontia is rarely the presenting feature leading to a diagnosis of a medical condition, however, one should always consider this in patients presenting with severe hypodontia. The most likely associated conditions are the Ectodermal Dysplasias, which are genetic disorders in which there are congenital birth defects in two or more ectodermal structures (Figure 5). There are approximately 200 types of Ectodermal Dysplasias and Table 3 outlines some of the clinical features of this condition. Genetic penetrance can be variable, so it is possible that, in very mild forms, a

medical diagnosis may have been missed. In patients with severe hypodontia, where some of the features listed in Table 3 are co-existing, it is worth referring the patient to a paediatric dermatologist through the family medical practitioner for confirmation of the diagnosis and genetic counselling, if necessary.

### Functional implications

Although very little research has been carried out on the functional implications of hypodontia, one study suggests that masticatory difficulty is seldom a problem in patients with severe hypodontia.<sup>13</sup>

### Educational implications

The dental management of severe hypodontia can place a considerable commitment on the family with the large number of appointments that are required for treatment and review over a prolonged period of childhood. Orthodontic treatment, which can last up to two years, can be during an educationally critical period for children and, if appointments are spaced every six weeks, may result in significant time off school. A child may suffer from other medical problems that require appointments with other hospital specialists, which may complicate matters further. It is important for clinicians to be empathetic about parental concerns in such cases. In order to reduce the impact of dental treatment on education, the following advice can be considered:

Parents should be advised to have the school diary when making appointments so that these can be placed during holiday periods whenever possible.

Children undergoing treatment during examination years should be prioritized to appointment slots after school.

If appointments must be scheduled during school times, care should be taken that the same lessons are not missed on every occasion and less educationally demanding subjects are missed (eg games).

### Financial implications

A diagnosis of hypodontia can

have financial implications for a family. At present in the United Kingdom the National Health Service funds dental care for children and, typically, implant related treatment for young adults with six or more missing teeth. With Primary Care Trust commissioning, it is possible that, in the future, there may be regional variations in the funding of such treatment. Another financial implication to be considered is the time parents have to take off work to accompany their children for treatment (particularly self-employed parents) and travel costs.

### Conclusions

The aim of this article is to provide guidance to dental practitioners about the advice that should be given to patients and parents who are faced with a diagnosis of hypodontia. As well as the dental consequences of such a diagnosis, we have also discussed the psycho-social, medical, functional, educational and financial implications. These are particularly relevant to individuals affected by more severe forms of hypodontia. The long-term nature of dental treatment of hypodontia dictates that patient information and parental involvement are particularly important for patient satisfaction and optimum treatment outcomes. As more research evidence becomes available, we will improve our understanding of the psycho-social and functional consequences of this condition.

#### Useful websites:

Bullying Online  
[www.bullying.co.uk](http://www.bullying.co.uk)  
 Ectodermal Dysplasia Society  
<http://www.ectodermaldysplasia.org/>  
 National Foundation for Ectodermal Dysplasias  
<http://www.nfed.org/>

### References

1. Polder BJ, Van't Hof MA, Van der Linden FPGM, Kuijpers-Jagtman AM. A meta-analysis of the prevalence of dental agenesis of permanent teeth. *Community Dent Oral Epidemiol* 2004; **32**: 217–226.
2. Hobkirk JA, Brook AH. The management of patients with severe

hypodontia. *J Oral Rehabil* 1980; **7**: 289–298.

3. Bergendal B, Koch G, Kurol J, Wänndahl G (eds). Consensus conference on ectodermal dysplasia with special reference to dental treatment. Stockholm, Sweden: Gothia, 1998.
4. Tarjan I, Gabris K, Rozsa N. Early prosthetic treatment of patients with ectodermal dysplasia: a clinical report. *J Prosthet Dent* 2005; **93**: 419–424.
5. Ellis RK, Donly KJ, Wild TW. Indirect composite resin crowns as an esthetic approach to treating ectodermal dysplasia: a case report. *Quintessence Int* 1992; **23**: 727–729.
6. Guckes AD, McCarthy GR, Brahim J. Use of endosseous implants in 3-year-old children with ectodermal dysplasia: case report and 5-year follow-up. *Pediatr Dent* 1997; **19**: 282–285.
7. Chung LK, Hobson RS, Nunn JH, Gordon PH, Carter NE. An analysis of the skeletal relationships in a group of young people with hypodontia. *J Orthod* 2000; **27**: 315–318.
8. Boulton MJ, Underwood K. Bully/victim problems among middle school children. *Br J Educ Psychol* 1992; **62**: 73–87.
9. Hawker DSJ, Boulton MJ. Twenty years research on peer victimisation and psychosocial maladjustment: a meta-analytic review of cross-sectional studies. *J Psychol Psychiatr Allied Disciplines* 2000; **41**: 441–455.
10. Olweus D. Victimization by peers: antecedents and long-term outcomes. In: *Social Withdrawal, Inhibition and Shyness in Childhood*. Rubin KH, Asendorpf JB, eds. Hillsdale, NJ: Lawrence Erlbaum Associates, 1993; pp.315–341.
11. DiBiase AT, Sandler PJ. Malocclusion, orthodontics and bullying. *Dent Update* 2001; **28**: 464–466.
12. Itin PH, Fistarol SK. Ectodermal Dysplasias. *Am J Med Gen Part C (Semin Med Genet)* 2004; **131C**: 45–51.
13. Hobkirk JA, Goodman JR, Jones SP. Presenting complaints and findings in a group of patients attending a hypodontia clinic. *Br Dent J* 1994; **177**: 337–339.